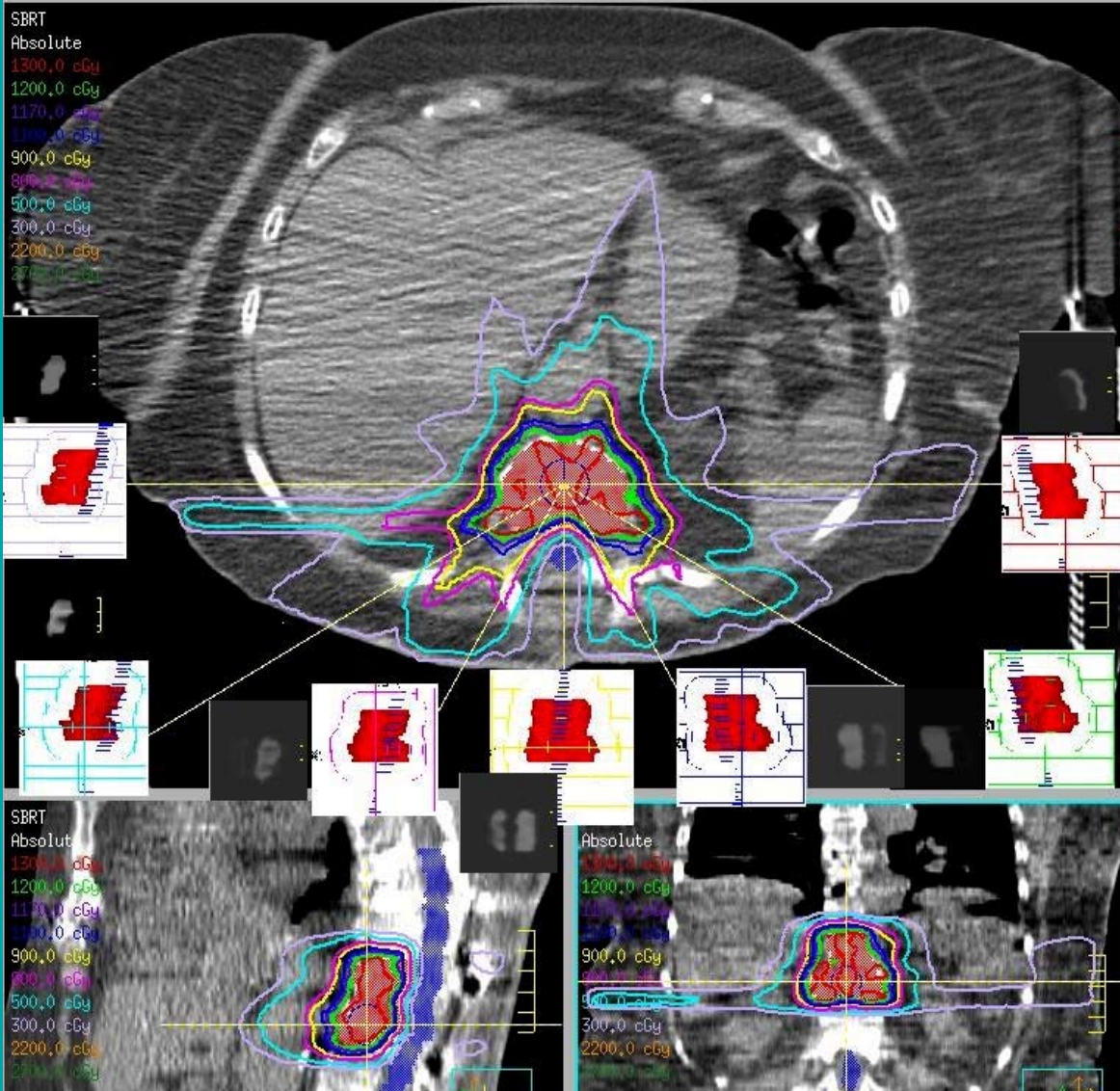

Re-treatment of a recurrent vertebral tumor using Elekta Synergy® S

Institution:	Temple University Hospital, Philadelphia, USA
Patient:	73-year-old female
Diagnosis:	Hürthle cell carcinoma of the thyroid
Plan:	Seven-field IMRT/SBRT
Image guidance:	VolumeView™ on-line
Positioning:	Body frame with vacuum mattress
Treatment:	Target – T12 vertebral body 1200cGy Spinal cord – 300cGy

Re-treatment of a recurrent vertebral tumor using Elekta Synergy® S

Radiation Oncologist:	Curtis Miyamoto, M.D., Professor & Chairperson
Radiation Oncologist:	Bizhan Micaly, M.D., F.A.C.R., Professor & Associate Chairperson
Instructor, Radiation Oncology:	Nicolas Kuritzky, M.D.
Medical Physicist:	Harold Perera, Ph.D., Ajaya Kumar Devabhaktuni, M.S. and Jen San Tsai, Ph.D.
Neurosurgeon:	Christopher Loftus, M.D., Professor and Chairperson,
Dosimetrist:	Roxana Taveira, B.S., C.M.D.

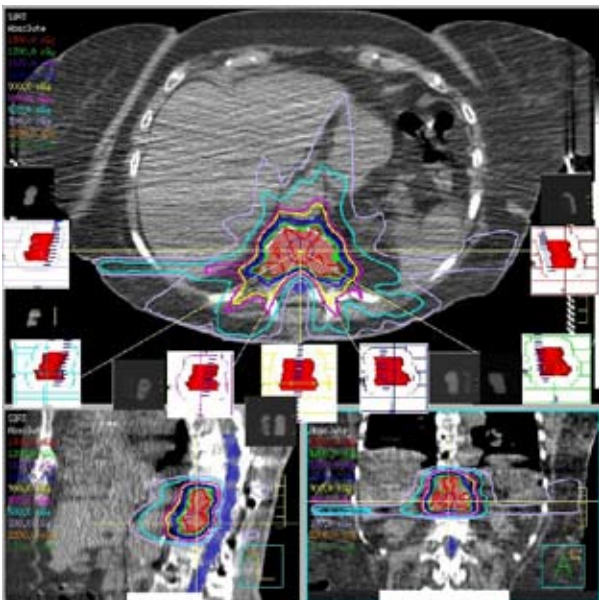
Patient diagnosis and history

A 73-year-old woman was originally diagnosed with a stage IV Hürthle cell carcinoma of the thyroid, metastatic to the lung, in 1994. The patient had previously undergone a thyroidectomy for a goiter in 1984. In 1994, the patient underwent multiple thoracotomies, radioactive iodine treatment and resection of lung metastasis in 1997 and 2001.

In 2002, the patient developed a metastatic lesion to the T11 vertebral body, measuring 3 x 3 x 3.5cm, with the involvement of the right pedicle and mild cord compression.

From October to November 2002 the patient underwent radiation therapy from T10 through to T12 vertebral body using a single posterior field delivering a total dose of 4000cGy, with 200cGy/fraction, calculated at 5cm depth, in 20 treatments.

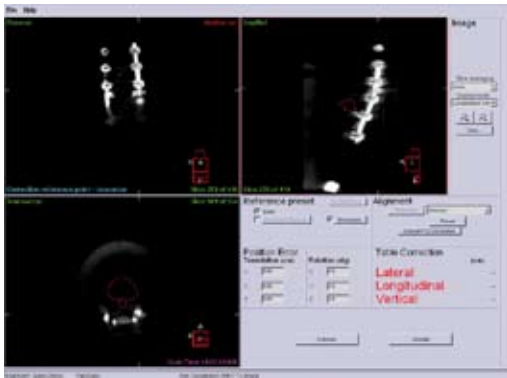
In 2003, the patient underwent surgery to the lumbar spine for spinal stenosis but following surgery experienced increasing back pain. In September 2005, the patient underwent a decompressive laminectomy from T10 through T12 with resection of her tumor at T11. Titanium rods were inserted for stabilization. The patient was felt to be at significant risk of residual disease, and therefore, a course of post-operative radiation therapy was recommended.



Treatment

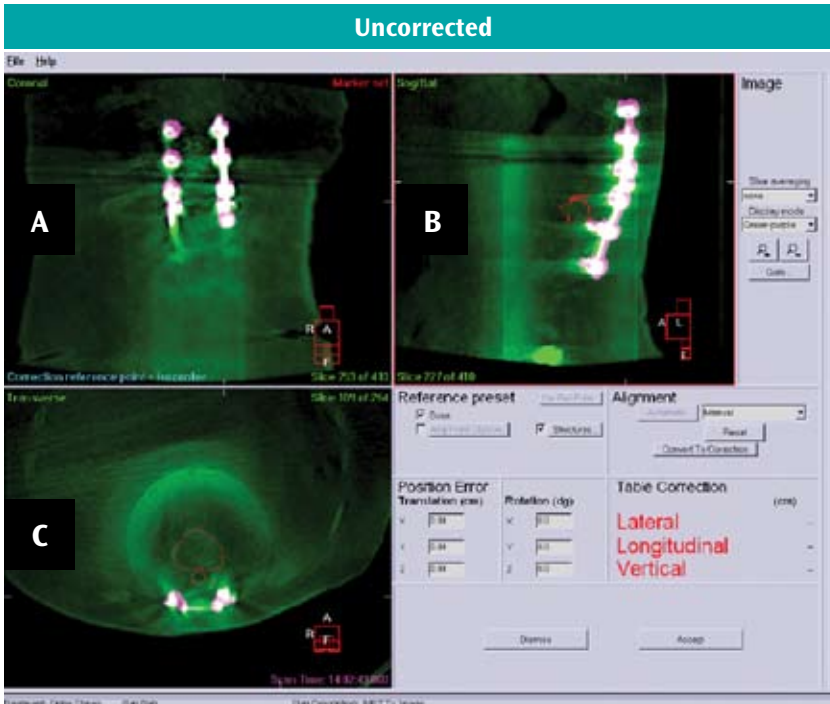
A step-and-shoot IMRT/stereotactic body radiation therapy (SBRT) plan (figure 1) was created for the treatment of a T11 relapse. Treatment planning was carried out using Philips Pinnacle®3 IMRT/SBRT techniques. The titanium rods were used as fiducial markers for targeting. The patient was positioned in a body frame with a vacuum mattress. No sedation was employed.

Figure 1: dose distribution for a seven-field IMRT plan with dose restricted to the spinal cord and kidneys.



The tumor was irradiated using seven fields with a single fraction of 1200cGy to the GTV. Dose to the spinal cord was restricted to a maximum dose of 300cGy. The dose to the right kidney was restricted to 240cGy and to the left kidney 300cGy. Patient positioning was verified using the titanium rods and XVI imaging. The titanium rods were aligned using bone window contrasting. Adjustments were made, and the patient was re-imaged (figure 2). Treatment was then delivered.

Figure 2: multi-planar reconstruction of VolumeView™ images used for patient position alignment, utilizing the titanium rods as internal markers.



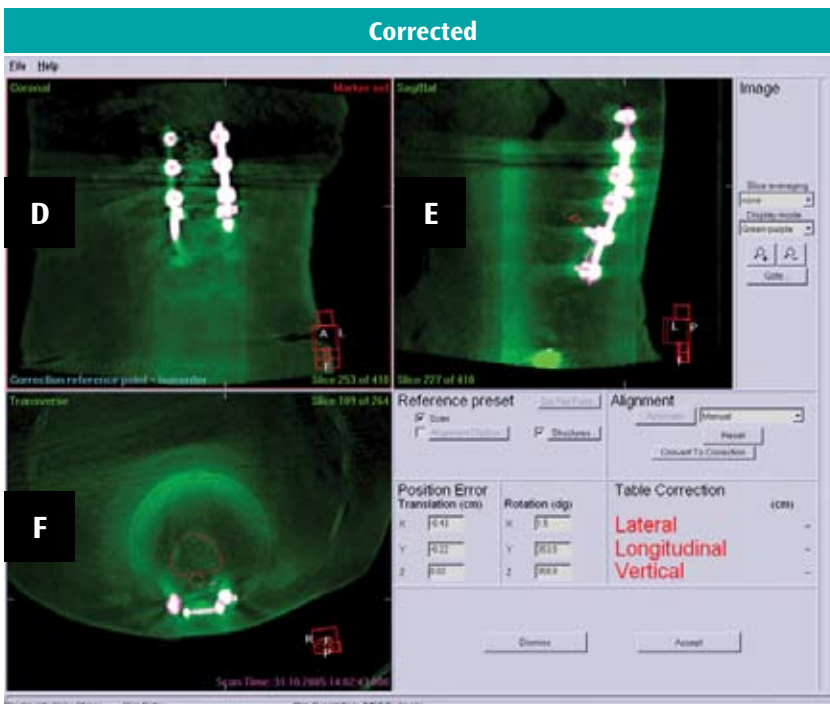
Treatment time¹ ≈ 50 minutes:

- 1 min. – acquisition
 - 4 mins. – registration
 - 3 mins. – repositioning
 - 1 min. – re-imaging
 - 1 mins. – re-registration
 - 37 mins. – treatment delivery
- ¹ Including patient set-up

Figure 3: VolumeView™ images taken using Elekta Synergy® S –

Images A to C position prior to registration and correction with structure overlay from the planning reference image.

Images D to F coronal, sagittal and axial positioning after correction drawn from the table correction vectors produced by VolumeView™



Outcome and follow-up

Ten months after treatment, the tumor remains clinically and locally controlled.

Discussion

IMRT/SBRT (which alone can reduce toxicity to OARs) combined with in-room XVI 3D volume imaging using titanium rods as fiducial markers allowed re-treatment at T11 with a single high-dose and maximum precision, resulting in a minimal dose exposure of the spinal cord and kidneys, with minimal additional time requirement. We expected significant image artifacts from the implanted titanium rods and were pleasantly surprised at the exceptional CBCT image quality, which allowed us to easily conduct 3D image registration.

Fighting serious disease

www.elekta.com

■ Stereotactic Neurosurgery ■ Gamma Knife® surgery ■ Functional Mapping ■ Precision Radiation Therapy ■ Image Guided Radiation Therapy ■ Stereotactic Radiation Therapy

Corporate Head Office
Stockholm, Sweden
Tel +46 8 587 254 00
Fax +46 8 587 255 00
info@elekta.com

Worldwide Product Support Center
Tel +44 01293 654068
Fax +44 01293 654655
info.europe@elekta.com

North America
Atlanta, USA
Tel +1 770 300 9725
Fax +1 770 448 6338
info.america@elekta.com

Europe, South America, Africa & the Middle East
Tel +44 1293 654068
Fax +44 1293 654655
info.europe@elekta.com

Japan
Kobe, Japan
Tel +81 78 241 7100
Fax +81 78 271 7823
info.japan@elekta.com

Asia-Pacific
Hong Kong, China
Tel +852 2891 2208
Fax +852 2575 7133
info.asia@elekta.com