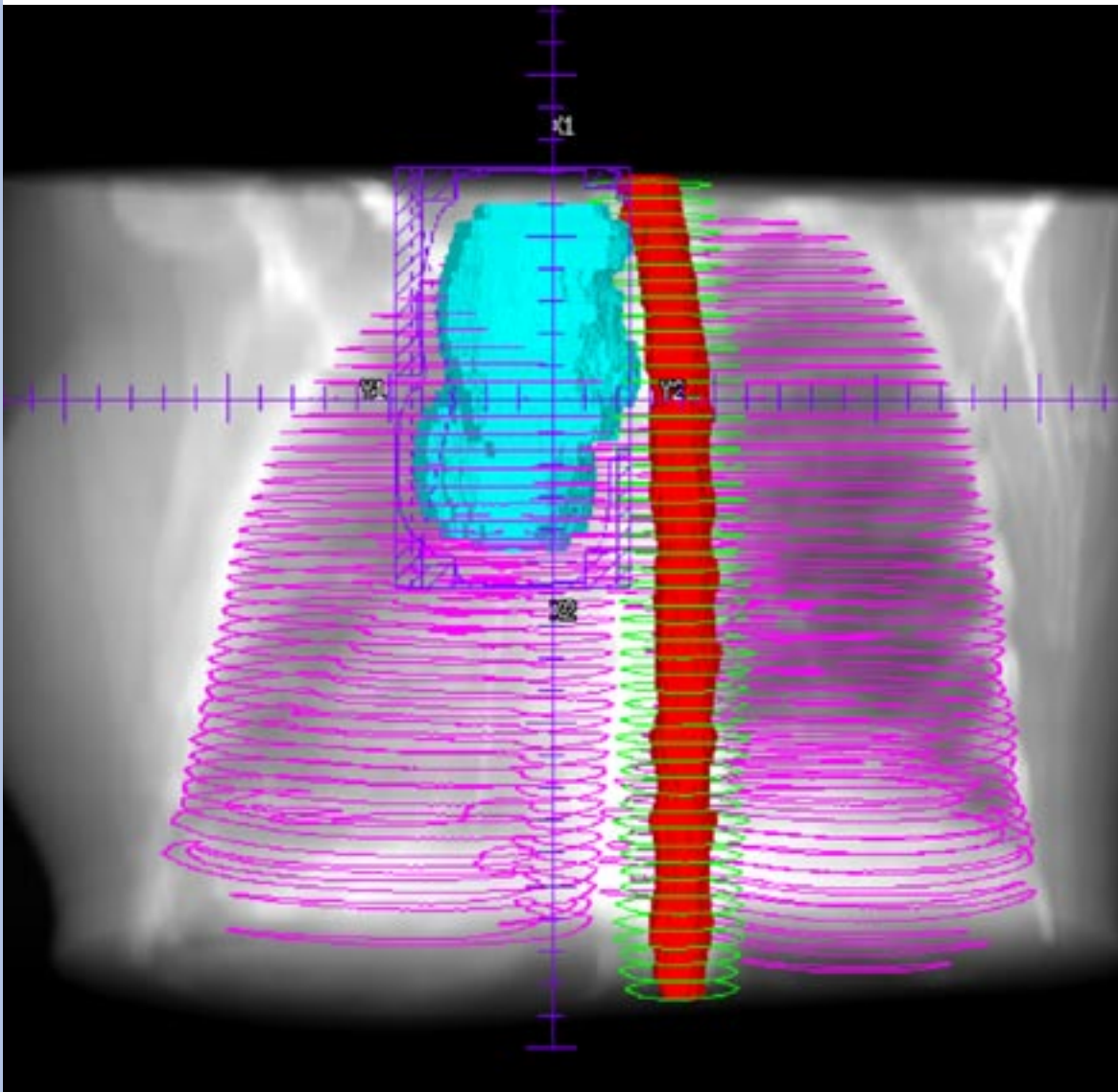

Off-line IGRT for a non-small cell lung tumor using Elekta Synergy®

Institution:	The Christie Hospital NHS Trust, Manchester, UK Wade Centre for Radiotherapy Research
Patient:	Female 53-years
Diagnosis:	Left lung, non-small cell, tumor
Plan:	Three-field wedged
Imaging:	Elekta VolumeView™ off-line protocol
Positioning:	Lung board
Treatment:	55Gy in 20 fractions over 25 days

Off-line IGRT for a non-small cell lung tumor using Elekta Synergy®

Radiation Oncologist **Dr C Faivre Finn**
Research Radiographers **Julie Davies, Julie Stratford, Claire McCarthy, Michelle Duffy**
Physicists **Medical Physics Planning Department, North Western Medical Physics**

Patient history and diagnosis

53-year-old woman presented in February 2005 with repeated chest infection. A CT scan showed a left lung mass and a soft tissue mass in relation to the left hilum. A biopsy showed consistency with non-small cell lung cancer.

The patient had no breathing difficulties and was commenced on down staging chemotherapy to which she had a partial response, with complete disappearance of left hilar mass and reduction of the apical tumor. Surgery was not possible as the tumor lay close to the pericardium and vital structures, primarily spinal cord. The patient was then referred for radiation therapy.

Planned treatment

A three-field wedged technique was planned using 6MV and delivering 55Gy to the isocenter in 20 fractions over 25 days (see figure 1). The planning system used was Philips Pinnacle®. There was an immediate request for Elekta VolumeView™ 3D imaging due to the proximity of the treatment to the spinal cord.

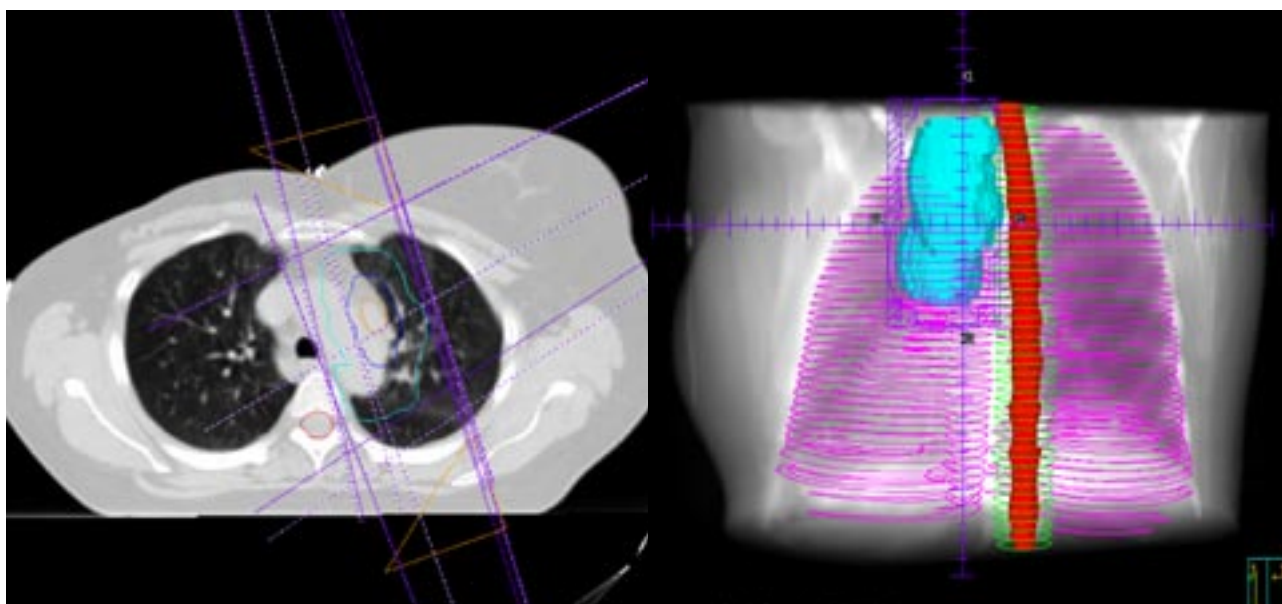


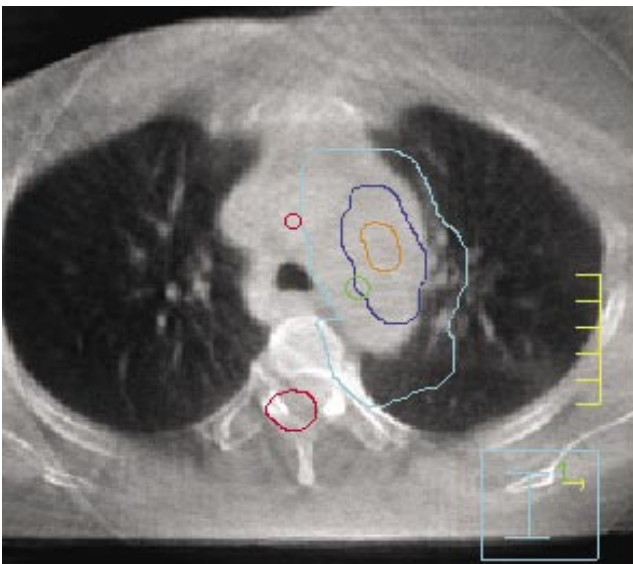
Figure 1: planned treatment

Image guidance

The patient was positioned supine and immobilized on a lung board with arms raised. Elekta VolumeView™ images were acquired and an off-line image registration protocol was implemented on the first three days of treatment. The acquired Elekta VolumeView™ images were used to assess for random and systematic errors in the patient position and to ensure PTV coverage and the position of the PTV in relation to cord proximity.

A systematic error was apparent in the lateral and vertical positions which resulted in the PTV moving closer to the spinal cord (see figure 2). An isocenter move was instigated and imaging, following an off-line registration protocol, was repeated for a further two days. It was found that systematic errors were then eliminated and weekly imaging was used for the remainder of the treatment.

Uncorrected



Corrected

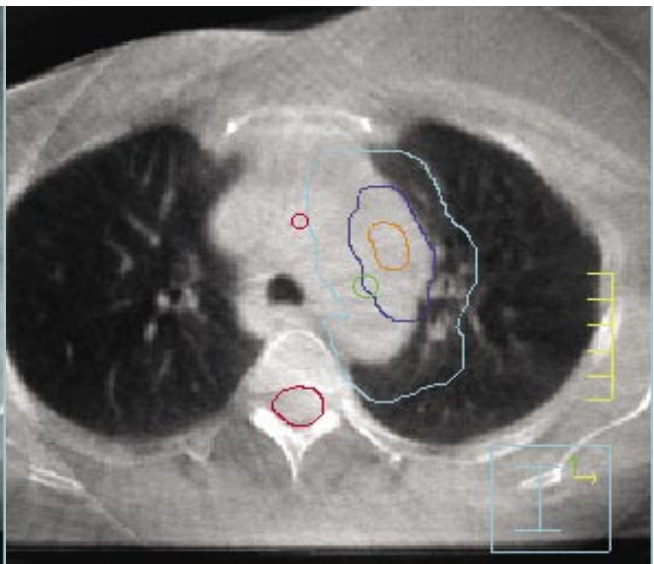

Figure 2: Elekta VolumeView™ pre-correction

Figure 3: Elekta VolumeView™ post-correction

Treatment time = 9 minutes:

- 3 mins. patient set-up
 - 2 mins. acquisition
 - 4 mins. treatment
 - 3 mins. off-line analysis
- The correction policy was off-line, taken over 3 days.

Imaging dose

- 6mGy Elekta VolumeView™ acquisition
- 3cGy Orthogonal MV EPID

The total treatment time was 12 minutes including Elekta VolumeView™ image acquisition.

(continued overleaf)

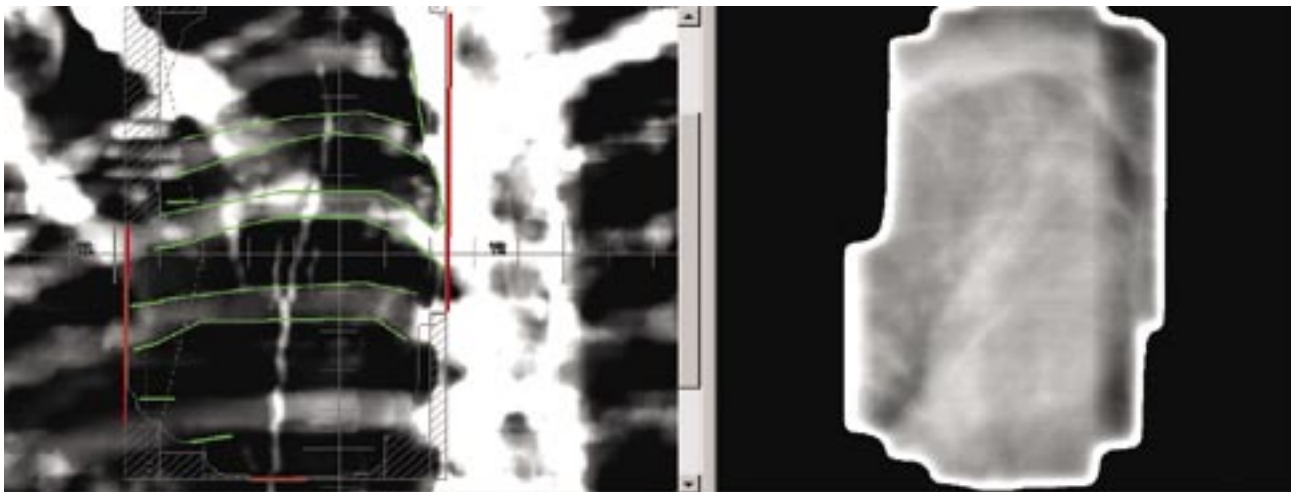


Figure 4: BEV LPO

Standard MV EPI using BEV images were of insufficient quality (see figure 4) for accurate matching and therefore not acceptable. Open orthogonal MV images were discounted as this technique would not account for patient rotation and would result in approximately 3cGy additional dose as opposed to 6mGy from Elekta VolumeView™ 3D imaging. This in turn has major impact in terms of ionizing radiation (medical exposure) regulations IR(ME)R and as low as reasonably practical principle (ALARP).

Discussion

The patient is now nine months post-radiation therapy and remains well.

The importance of this treatment and the use of Elekta VolumeView™ 3D imaging is the ability to offer patients a radical course of treatment, due to the increased confidence in our verification techniques and our ability to eliminate systematic error. This factor is vital when there are so many treatment restrictions due to the proximity of the treatment to critical structures.

We now have the technological capabilities to introduce enhanced treatment verification routinely into clinical practice for the benefit of patients without extending treatment times or impacting on patient waiting lists.

Departmental policy now ensures that all lung patients with a PTV close to critical structures will have Elekta VolumeView™ 3D imaging, with a gradual transfer of all lung cancer patients to an image guided radiation therapy protocol using Elekta Synergy® and VolumeView™.

Fighting serious disease

www.elekta.com

■ Stereotactic Neurosurgery ■ Gamma Knife® surgery ■ Functional Mapping ■ Precision Radiation Therapy ■ Image Guided Radiation Therapy ■ Stereotactic Radiation Therapy

Corporate Head Office
Stockholm, Sweden
Tel +46 8 587 254 00
Fax +46 8 587 255 00
info@elekta.com

Worldwide Product Support Center
Tel +44 01293 654068
Fax +44 01293 654655
info.europe@elekta.com

North America
Atlanta, USA
Tel +1 770 300 9725
Fax +1 770 448 6338
info.america@elekta.com

Europe, South America, Africa & the Middle East
Tel +44 1293 654068
Fax +44 1293 654655
info.europe@elekta.com

Japan
Kobe, Japan
Tel +81 78 241 7100
Fax +81 78 271 7823
info.japan@elekta.com

Asia-Pacific
Hong Kong, China
Tel +852 2891 2208
Fax +852 2575 7133
info.asia@elekta.com